

LESSER DIGITAL FUSION PATIENT OUTCOMES WITH TRILLIANT TWO-STEP, COMPARED TO SMART TOE® AND PHALINX™, LEADING TO BETTER PROFITABILITY

Presented by
Antonio Montemurro, DPM, ABPM

HAMMER TOE CORRECTION

Introduction

Lesser digital arthrodesis is a common procedure for hammertoe correction. Many techniques of bone resection¹⁻⁷ as well as fixation⁸⁻¹² have been used with variable success. The purpose of this article is to present a technique using Trilliant Surgical Two-Step Hammer Toe Implant System that is simple, reliable, and effective with several key advantages over those previously reported.

Surgical Technique

A dorsal linear longitudinal approach is used to access both the proximal interphalangeal joint (PIPJ) and distal interphalangeal joint (DIPJ). A transverse tenotomy/capsulotomy to enter the PIPJ is employed next. A convex resection of the opposing proximal phalanx of the PIPJ joint surface is performed, followed by a concave surface resection of the opposing middle phalanx of the PIPJ surface utilizing the included HTR® reaming instrumentation. Using a spade drill corresponding to the chosen implant spade, drill a pilot hole in the head of the proximal phalanx in the proper alignment and position for implant placement. The pilot drill is self-stopping.

A single .045 Kirschner wire (K-wire) is driven into the middle phalanx, with care, to centralize the wire within the phalanx. Be sure to continue driving the K-wire until it is protruding through the distal phalanx. Confirm that the K-wire is sufficiently exposed to allow for capture with the wire pin driver. With the wire pin driver, retract the K-wire distally until the proximal end is exposed approximately 5mm. Ensure that the proper sized implant can be performed with use of fluoroscopy. Select the appropriate length and diameter implant and slide the implant over the exposed proximal end of the K-wire. Using the driver, drive the implant into the middle phalanx until the leading edge of the tri-spade stem abuts the edge of the middle phalanx. Make sure a fin of the tri-spade stem sits in the 12 o'clock (dorsal) position.

Manually distract the middle phalanx and align the tri-spade stem down the central axis of the head of the proximal phalanx. Finally, apply firm compression until the base of the middle phalanx fully apposes the head of the proximal phalanx.

Additional tendinous or capsular releases of the metatarsophalangeal joint (MTPJ) or DIPJ are performed as indicated. The patient may be full weightbearing in a surgical shoe immediately postoperatively, with a half-inch piano-felt liner from heel to sulcus if a K-wire is crossing the MTPJ. The protective shoe is maintained for approximately six weeks.

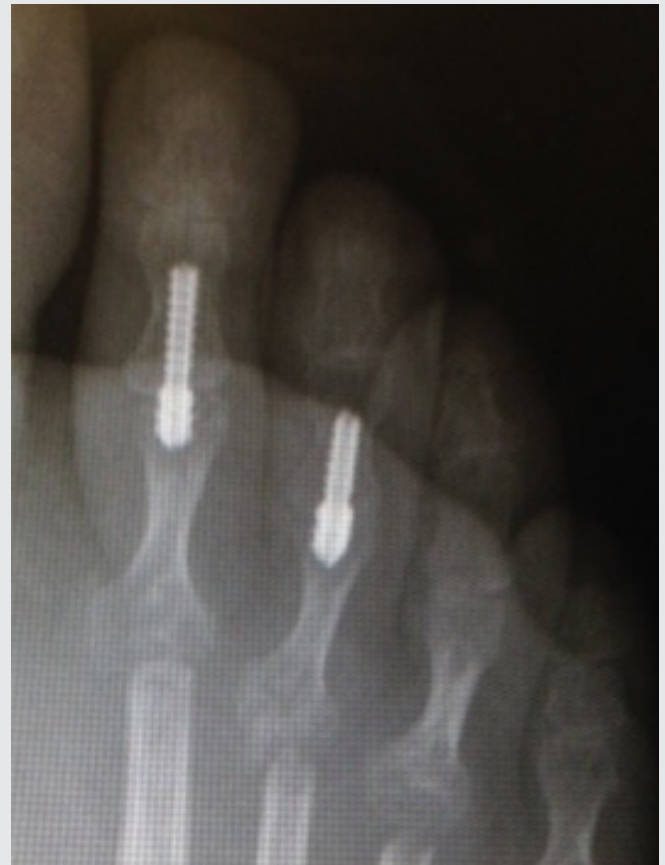

Figure 1. Anterior posterior radiograph showing completed digital fusion with the cannulated implant.

Advantages

The advantages of this technique include a low chance of mal/non-union due to this redundant, extremely stable, compressive fixation, quicker potential return to activity, ease of hardware (K-wire) removal, and the capability to temporarily stabilize the MTPJ with K-wire fixation so that adjunctive MTPJ procedures can heal while reinforcing the PIPJ construct.

Potential intra-operative complications may include stripping of the implant and fracture of the cortical wall of either phalanx. With careful attention to technique, these are avoided. In the case of cortical wall fracture, K-wire and/or cerclage wire may be necessary. In over 20 of these fusions during the past three years, additional fixation has not been necessary. All cases have gone on to heal successfully without need to remove fixation.

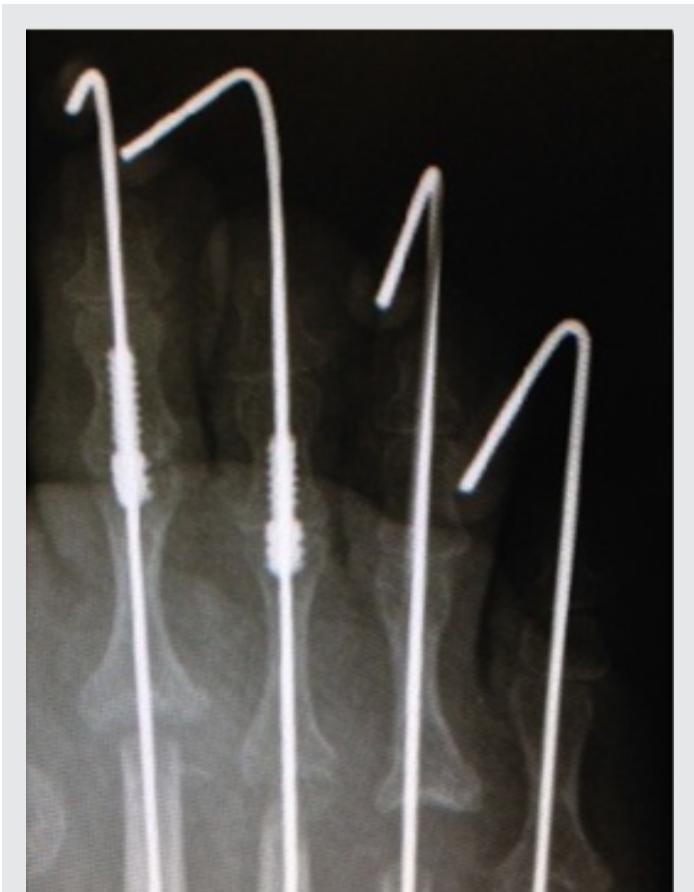

Figure 2. Anterior posterior radiograph of digital fusion and cannulated guide pin. The pin crosses and stabilizes the MTPJ.

Clinical Study

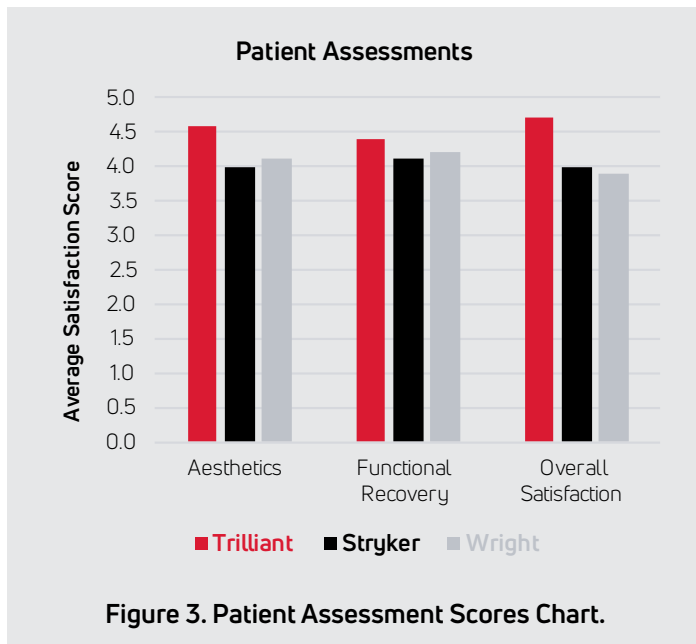
A retro-active clinical study was created to assess the success rates of different digital arthrodesis procedures. Of the 101 arthrodesis evaluated, 53 of were Trilliant Two-Step Implants, 23 were Stryker Smart Toe® Implants, and 25 were the Phalinx™ by Wright Medical. The procedures took place over a five year period from January of 2012 to January of 2017. Success was measured via a Patient Satisfaction Survey given six months after recovery. The data used for this particular study, were patient satisfaction ratings in three categories: Aesthetics, Functional Recovery, and Overall Satisfaction. The Trilliant Two-Step had average aesthetic, functional level and satisfaction ratings of 4.6/5.0, 4.4/5.0 and 4.7/5.0 following surgery. This is deemed to be significantly higher than both the Smart Toe and Phalinx. The Smart Toe had averages of 4.0/5.0, 4.1/5.0 and 4.0/5.0, while the Phalinx scored 4.1/5.0, 4.2/5.0 and 3.9/5.0, respectively, for the same criteria (Figure 3).

In Conclusion

When evaluating any surgical procedure, such as the hammer toe implants in this study, we chose patient satisfaction as the key feature for determining our future hardware. More than half (54%)¹³ of healthcare executives say patient experience and satisfaction is one of their top three priorities.

Based in part on these types of patient satisfaction scores, hospitals can either lose or gain up to 2.0 % of their Medicare payments in fiscal year 2017¹³.

There is also a direct link between Patient Satisfaction scores and profitability. Based on data from 3,035 U.S. acute-care hospitals, 25% of hospitals with the highest HCAHPS (Hospital Consumer Assessment of Healthcare Providers and Systems) scores, such as that used in this study, were also the most profitable. In fact, only the hospitals in the top quartile for patient ratings showed a positive profit margin¹⁴.



The healthcare industry is undergoing massive changes, moving from a volume-based care model to a quality-based care model. In order to adapt to these fundamental changes, healthcare organizations are rapidly changing the way they do business, and their evolving product choices reflect that. Gone are the days of getting the cheapest product in volume, Instead, those old initiatives must also have a positive impact on both staff and patient satisfaction, providing hospitals and health systems with a solid foundation that will sustain them in both the short run and the long haul.

This study shows that not only is the Trilliant system easier to use, making staff satisfaction higher, but the patients demonstrate better outcomes, increasing patient satisfaction.

Innovations in foot and ankle surgery are advancing quickly and intramedullary hammertoe implants are at the forefront. The inherent benefits of such devices clearly demonstrate their place in hammertoe corrective surgery. It is my opinion that devices such as the HTR (Hammer Toe Reaming Implant System along with the Trilliant Two-Step Implant, will become the new gold standard in the years to come, providing both surgeon and patient satisfaction, and hospital profitability.

References

1. Soule RE. Operation for the cure of hammertoe. *N Y Med J* 91:649– 650, 1910.
2. Taylor RG, Sheffield FRCS. An operative procedure for the treatment of hammer-toe and claw-toe. *J Bone Joint Surg* 22:608–609, 1940.
3. Selig S: Hammer-toe: a new procedure for its correction. *Surg Gynecol Obstet* 72:101–105, 1941.
4. Higgs SL. Hammer-toe. *Med Press* 131:130–131, 1931.
5. Young CS: An operation for the correction of hammertoe and claw-toe. *J Bone Joint Surg* 20A:715–719, 1938.
6. Schelfman BS, Fenton CS III, McGlamry ED. Peg in hole arthrodesis. *J Am Podiatr Assoc* 73:187–195, 1983.
7. Pichney GA, Derner R, Lauf E. Digital “V” arthrodesis. *J Foot Surg* 32:473–479, 1993.
8. Reece HW. Reece arthrodesis screw: osteosynthesis of the interphalangeal joints. *J Am Podiatr Assoc* 77:490–494, 1987.
9. Coughlin MJ, Dorris J, Pok E. Operative repair of fixed hammertoe deformity. *Foot Ankle Int* 2000; 21:94-104.
10. Caterini R, Farsetti P, Tarantino U, Potenza V, Ippolito E. Arthrodesis of the toe joints with an intramedullary cannulated screw for correction of hammertoe deformity. *Foot Ankle Int* 2004;25:256-61.
11. Lamm BM, Riberio CE, Vlahovic TC, Fiorilli A, Bauer GR, Hillstrom HJ. Lessor proximal interphalangeal joint arthrodesis: a retrospective analysis of the peg-and-hole and end-to-end procedures. *J Am Podiatric Med Assoc* 2001;91:331-6.
12. HealthLeaders Media’s 2013 Industry Survey data.
13. “Frequently Asked Questions: Hospital Value-Based Purchasing Program.” Accessed April 6, 2015. <http://www.cms.gov/Medicare/Quality-Initiatives-Patient-Assessment-Instruments/hospital-value-based-purchasing/Downloads/FY-2013-Program-Frequently-Asked-Questions-about-Hospital-VBP-3-9-12.pdf>.
14. “Press Ganey 2011 Pulse Report: Perspectives on American Health Care.” Accessed April 6, 2015. http://www.pressganey.com/Documents_secure/Pulse%20Reports/2011_Press_Ganey_Pulse_Report.pdf.

All product and company names are trademarks™ or registered® trademarks of their respective holders. Use of them does not imply any affiliation or endorsement.



T 800.495.2919 F 877.778.3864
727 North Shepherd Drive, Suite 100 | Houston, TX 77007 | U.S.A.
djoglobal.com

Copyright © 2021 by DJO, LLC
900-30-001 Rev. D

NOTE: The views and opinions expressed in this white paper are those of the author. DJO, LLC is a manufacturer of orthopedic implants and does not practice medicine. Only an orthopedic, or foot and ankle surgeon can determine what treatment is appropriate. The contents of this document do not constitute medical, legal, or any other type of professional advice. This material is intended for the sole use and benefit of the DJO, LLC sales force and physicians. It is not to be redistributed, duplicated, or disclosed without the express written consent of DJO, LLC. For more information on risks, warnings, and possible adverse side effects refer to the Instructions for Use provided with the device.